

e-ISSN: 2345-0592 Online issue Indexed in <i>Index Copernicus</i>	Medical Sciences Official website: www.medicosciences.com	
--	--	---

Janssen COVID-19 vaccine-related acute myocarditis

Gabriele Kybartaitė¹, Gabriele Rudokaite², Jolanta Laukaitienė²

¹*Faculty of Medicine, Academy of Medicine, Lithuanian University of Health Sciences, Lithuania*

²*Department of Cardiology, Hospital of Lithuanian University of Health Sciences Kaunas Clinics, Lithuania*

Abstract

Introduction: according to reports, there is a link between the development of myocarditis and the use of coronavirus vaccines.

Case presentation: we present two cases of male adolescents aged 19 and 49 who developed acute myocarditis within a few days after receiving the second dose of the Janssen vaccine. They presented with acute chest pain, elevated troponins, and ST elevations in the precordial leads without reciprocal changes. Although there is no formal evidence, the presentation patterns and clinical course are associated with the COVID-19 vaccine. Myocarditis was confirmed by cardiac magnetic resonance. During their hospitalization, both patients' hemodynamic status remained stable. There was no evidence of an infectious or autoimmune etiology.

Conclusions: myocarditis is a rare complication following SARS-CoV-2 vaccination and benefits of vaccination outweigh the risks and should not be avoided, especially for patients with underlying heart disease.

Keywords: acute myocarditis, COVID-19, Janssen vaccine

1. Introduction

Myocarditis is characterized by progressive inflammation of the middle layer of the heart, followed by myocardium injury without ischemic events. Either infectious or non-infectious agents can cause myocarditis [1]. One of the causes of non-infectious myocarditis is myocarditis as an adverse reaction to the vaccine. It was primarily described for the smallpox vaccine [2] and a few cases of myocarditis following the seasonal influenza vaccine in otherwise healthy adults, but the relationship is difficult to establish, and the case reports could have been due to chance [3]. COVID-19 vaccination began in Lithuania in late December 2020 with mRNA vaccines from Pfizer-BioNTech and Moderna; the Janssen vaccine was introduced more recently in April 2021, and people over the age of 18 may have been vaccinated. Using mRNA-based vaccines, immunization against COVID-19 and other viral pathogens is a new and promising technology [4]. Systemic adverse reactions after the second dose were reported more frequently in clinical trials, primarily in younger males, with a median onset time of one to two days [5].

2. Case presentation

2.1 Case nr. 1

A 19-year-old previously healthy male arrived at the emergency department (ED) and presented with a chief complaint of non-radiating chest pain of 3 days duration. He reported pressure-like, dull pain, 8-9/10 intensity, not relieved by non-steroidal anti-inflammatory drugs or paracetamol. He reported receiving the second dose of the COVID-19 Janssen vaccine four days before the symptoms. Soon after the vaccination, he had a fever up to 39°C that lasted for three days; the day after, chest pain occurred. He had no previous history of viral illnesses and no known COVID-19 exposure. ECG demonstrated sinus

rhythm, HR 80 bpm, ST elevation in the precordial leads without reciprocal changes, as it is shown in Figure 1. CRP was 43.78 mg/l (normal 0-5 mg/l), troponin T 535.6 ng/l (normal 0-14 ng/l), leukocytes $10.07 \times 10^9/l$ (normal 3.6-10.2 $\times 10^9/l$) and BNP 74.2 ng/l (normal 0-26.5 ng/l) thus he was transferred to University hospital for a cardiologist evaluation (Table 1).

The laboratory testing showed high troponin I levels – 9.12 g/l (normal 0-0.04g/l); bedside echocardiography revealed hypokinetic posterior and inferior walls of the left ventricle. Coronary angiography showed no signs of stenosis. The myocarditis was suspected, and the patient was admitted to the Department of Cardiology. The cardiac MRI revealed an increase in end-diastolic volume (EDV), an increase of end-systolic volume (ESV), decreased ejection fraction (EF) (40 %), areas with elevated signal intensity in T2 sequence indicating edema, late gadolinium accumulation and signs of acute myocardial injury subepicardial, mostly on basal segments of inferior and posterior walls, as shown in Figure 2. No signs of significant arrhythmias or conduction disturbances were registered. An echocardiogram performed on the third post-admission day revealed a dilated left ventricle (LV), poor contraction of the inferior, posterior, and lateral walls, and inferior part of the interventricular septum. The patient received intravenous ketorolac 30 mg p.r.n for pain. Troponin level decreased 50 % over the first two 48 hours and almost reached a normal level (0.06 g/l) on the day of discharge. He was discharged from the hospital on day six due to improved symptoms and a lower troponin level. At the time of this submission, the patient had not yet returned for a follow-up visit.

Table 1. Summary of diagnostics in two patients with symptomatic myocarditis following the second dose of Janssen COVID-19 vaccine.

	Patient 1	Patient 2
Troponin I	8.18	9.75
Highest troponin	8.18	9.75
Lowest troponin (before discharge)	0.06	0.04
BNP	74.2	97.1
CRP	57.1	5.0
COVID-19 PCR result	Negative	Negative on the day of admission, positive before discharging
ECG	Sinus rhythm, T-wave abnormality, signs of early repolarisation, ST elevation in leads V7 – V9	Sinus rhythm, ST elevation in the precordial leads without reciprocal changes
Echocardiogram	Moderate dilation of LV, poor basal segments of LV contraction	Poor LV contraction, decreased EF, higher pericardium intensity
Cardiac MRI	LGE (subepicardial) involving inferior and posterior LV basal segments; myocardial edema of anterior LV wall, apex, and all basal segments; decreased EF.	LGE (subepicardial and midventricular) involving lateral LV wall and apex; myocardial edema of apical segments.

* Except for the lowest troponin recorded before discharge, laboratory test values were chosen on the day of admission. LGE – late gadolinium enhancement; LV – left ventricle; EF – ejection fraction;

Figure 1. ECG showing ST elevation in the precordial leads without reciprocal changes

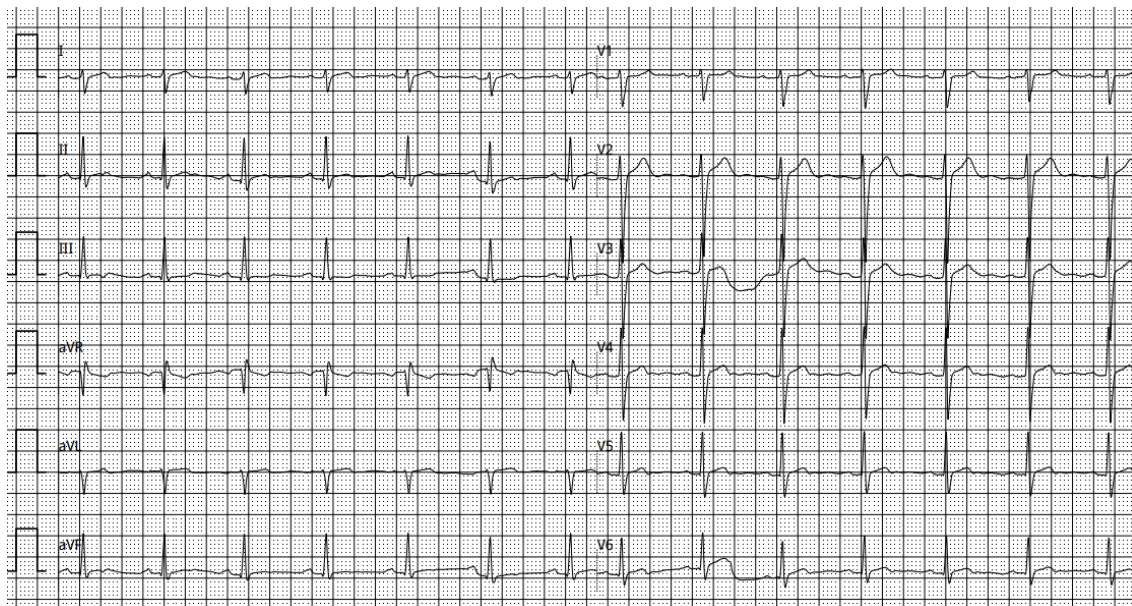
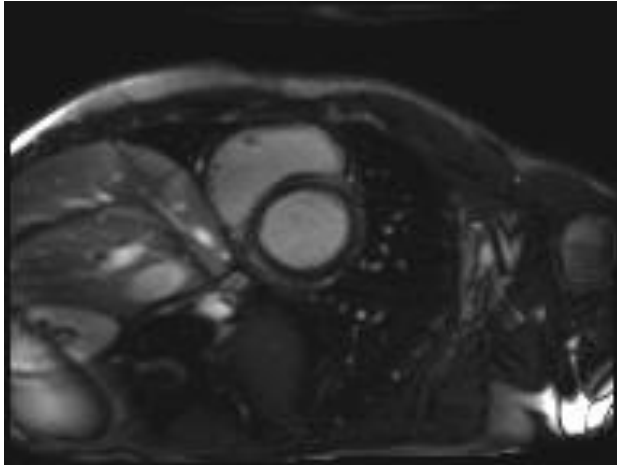


Figure 2. Cardiac MRI showing signs of late gadolinium enhancement



2.2 Case nr. 2

A 49-year-old male presented to the emergency department with a chief complaint of acute chest pain that radiates to the shoulders and left arm and is evaluated 10/10 in intensity. The patient stated that he was suffering from chest pain for the second time. He claimed that he had received the second dose of the COVID-19 Janssen vaccine two days prior to the onset of the symptoms. He had no prior history of viral illnesses and had never been exposed to COVID-19. The primary evaluation consisted of ECG, which showed sinus rhythm, HR 102 bpm, ST elevation in the precordial leads without reciprocal changes, as shown in Figure 3; laboratory testing, which revealed an elevated troponin I 3496 (normal up to 100), echocardiography showed signs of the hypokinetic interventricular septum and anterior wall of the left ventricle (Table 1). He was prescribed dual antiplatelet therapy and transferred to the university hospital's emergency department. He received anticoagulant therapy and was admitted to the cardiac intensive care unit (CICU) for further differentiation between acute coronary syndrome (ACS) and myopericarditis. Urgent cardiac catheterization revealed less than 50 % lumen stenoses, and ACS diagnosis was rejected. He

was transferred to the Department of Cardiology for further investigations and treatment. X-ray showed no signs of pericardial effusion. Premature ventricular complex (PVC) triplets were detected using Holter monitoring. For the confirmation of the diagnosis, MRI was done and revealed normal EF (69 %), increased EDV, higher signal intensity in T2 sequence indicating edema in apical regions, late gadolinium accumulation, all primarily in the subepicardial and midventricular apical and lateral LV free wall, also in the interventricular septum, as shown in Figure 4. The patient received ibuprofen 600 mg orally three times a day. When the treatment began, myocardial damage markers were significantly reduced. On day nine, he was discharged from the hospital due to improved symptoms and a lower troponin level. The day before discharge, a positive COVID-19 PCR result was found. His outpatient follow-up appointment is in 30 days. At the time of this submission, he had not yet returned for a follow-up visit.

Figure 4. Cardiac MRI showing higher signal intensity in T2 and late gadolinium enhancement.

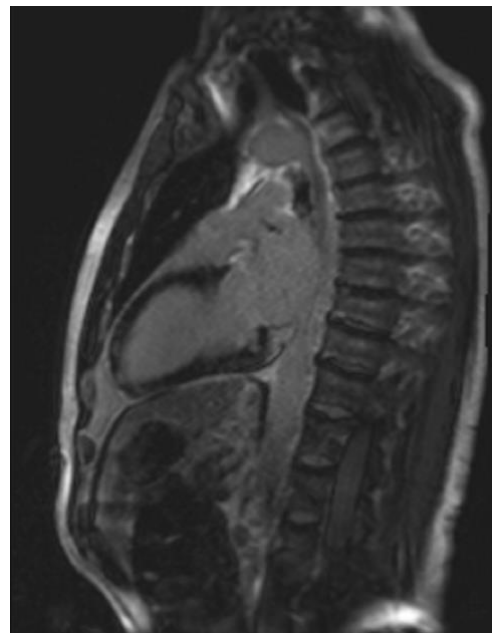
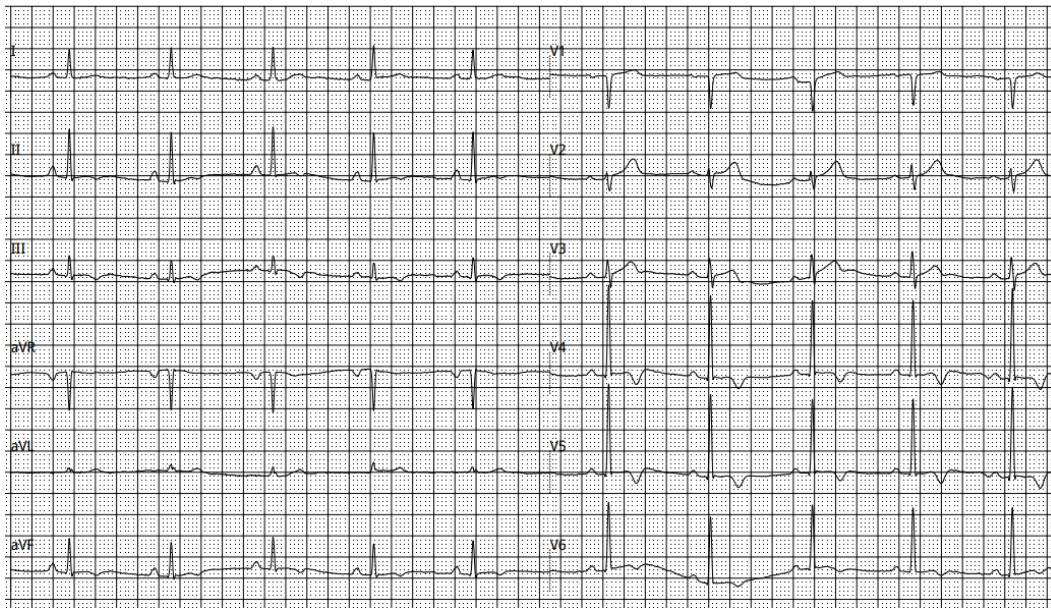


Figure 3. ECG with ST elevation in the precordial leads without reciprocal changes.

3. Discussion

3.1 COVID-19 vaccines and myocarditis

The coronavirus disease-2019 (COVID-19) outbreak was declared a pandemic by the World Health Organisation (WHO) on 11 March 2020, and the development of an effective COVID-19 vaccine rapidly became a global priority. Indeed, vaccination is a settled component of preventive medicine but is not without risk. COVID-19 vaccines mostly lead to minor side effects, such as pain, redness, or swelling on the injection site, and systemic symptoms, such as fatigue, headache, or fever [6]. Viral infection is one of the most common causes of myocarditis, mainly associated with influenza and parvovirus B19 infection. Vaccines can also cause myocarditis, and the most robust associations have been reported with the smallpox vaccine [7], but it is considered an unusual adverse event after vaccination [8]. The Janssen COVID-19 vaccine has been granted an Emergency Use Authorization (EUA) for individuals 18 years old and older. Like our patients, most reported cases describe young male patients with no

past cardiac medical history, presenting with chest pain within a few days after their second vaccine dose of COVID-19 vaccine and finally diagnosed with myocarditis. Li et al. [9] noted the incidence rate and risk for myocarditis and pericarditis following COVID-19 vaccination in the US according to age and type of vaccine. The incidence rate of myocarditis/pericarditis was 5.64/1 million doses after receiving the Janssen vaccine, 4.98/1 million doses after receiving the Moderna vaccine, and 6.70/1 million doses after receiving the Pfizer-BioNTech vaccine. Janssen was not associated with a higher incidence rate of myocarditis/pericarditis in comparison to other vaccines (odds ratio 1.39; 95 % CI, 0.99-1.97). Distribution according to gender was 34.6 % female and 65.4 % male [9]. Although age (mainly <30 years) and sex (mainly male) may modify general considerations of the small risk for myocarditis after COVID-19 vaccination, a discussion should consider an individual personal risk based on their health status [10]. Another study of individuals was conducted by Takuva et al. [11], where they reported data about the

frequency and incidence rate of myocarditis in South African individuals who were vaccinated with the Janssen vaccine. It was found that the median age of the total population was 42 year, and the majority was women. The incidence of myocarditis was 1.06 per 100 000 participants [11]. Analysis of Vaccine Adverse Effects Reporting System (VAERS) for episodes of myocarditis following COVID-19 vaccination was significant for an increased prevalence of myocarditis in males, consistent with prior findings. Individuals below 40 years old, who accounted for 32 % of the total full vaccination, resulted in 81 % of the myocarditis case in VAERS. As there is widespread vaccine distribution, increasing cases of myocarditis have been detected with the mRNA vaccines. Since the Janssen vaccine has a similar end product as the mRNA vaccines, further cases of myocarditis with the Janssen vaccine may be expected [12, 13].

3.2 Diagnosis of vaccine caused myocarditis

Centers for Disease Control and Prevention (CDC) recommends ECG, troponin level, and inflammatory markers such as C-reactive protein and erythrocyte sedimentation rate for initial evaluation of COVID-19 vaccines caused myocarditis. Myocarditis is unlikely in the setting of normal ECG, troponin, and inflammatory markers [14]. A recent systematic review revealed that myocarditis mainly progresses with marked elevation in cardiac troponins, CK-MB, BNP, and CRP in COVID-19 vaccine patients with myocarditis [15]. ECG is considered a second-order investigation due to the insufficient specificity of the findings. However, most ECGs have one of the following: ST elevation, PR depression, new-onset of bundle branch block, QT prolongation, pseudo-infarct patterns, PVC, bradyarrhythmia with an advanced atrioventricular nodal block [16]. American Heart Association (AHA) recommends that patients with

clinical and biochemical abnormalities of myocarditis require to be tested with further imaging modalities, such as echocardiogram and cardiovascular magnetic resonance (CMR) [17]. Echocardiography helps determine potential complications and evaluate possible abnormalities, such as higher wall thickness, chamber dilation, pericardial effusion, global or regional hypokinesia, and systolic dysfunction. CMR helps to determine myocardial edema and injury and pericardial effusion. It also includes T1/T2-weighted imaging criteria for myocardial inflammation [17]. It is essential to rule out other possible causes of the presentation, specifically acute coronary syndromes and other cardiovascular or extra-cardiac non-inflammatory diseases that could explain the clinical presentation. In our cases, cardiac catheterization has been performed, and acute coronary syndromes were ruled out.

4. Conclusion

Myocarditis is a rare complication following SARS-CoV-2 vaccination. Although the actual incidence of myocarditis following mRNA COVID-19 vaccines is unknown, this raises concerns about the potential for adverse cardiovascular effects, particularly in young patients. Based on current knowledge, the benefits of vaccination outweigh the risks and should not be avoided, especially for patients with underlying heart disease.

References

1. Krejci J, Mlejnek D, Sochorova D, Nemecek P. Inflammatory Cardiomyopathy: A Current View on the Pathophysiology, Diagnosis, and Treatment. *Biomed Res Int*. 2016. 2016:4087632.
2. Mandra A, Superior M, Guagliardo S, Hesse E, Pacha L, Stidham R et al. Myopericarditis Associated With Smallpox Vaccination Among US Army

Personnel – Fort Hood, Texas, 2018. *2004*; 44(1):201-205.

3. Kim Y, Bae J, Ryoo S, Kim W. Acute fulminant myocarditis following influenza vaccination requiring extracorporeal membrane oxygenation. *Acute Crit Care*. 2019; 34(2):165-169.

4. Faix D, Gordon D, Perry L, Raymond-Loher I, Tati N, Lin G et al. Prospective safety surveillance study of ACAM2000 smallpox vaccine in deploying military personnel. 2020. *Vaccine*, 38 (2020), pp. 7323-7330

5. Faix D, Gordon D, Perry L, Raymond-Loher I, Tati N, Lin G et al. Prospective safety surveillance study of ACAM2000 smallpox vaccine in deploying military personnel. *N Engl J Med*, 383 (2020), pp. 2604-2615

6. What to Expect after Getting a COVID-19 Vaccine [Internet]. Centers for Disease Control and Prevention. 2021.

7. Keinath K, Church T, Kurth B, Hulten E.: Myocarditis secondary to smallpox vaccination. *BMJ Case rep* 2018

8. Abbasi J. Researchers Investigate What COVID-19 Does to the Heart. *JAMA*. 2021;325(9):808-811.

9. Li M, Yuan J, Lv G, et al. Myocarditis and pericarditis following COVID-19 vaccination: inequalities in age and vaccine types. *J Pers Med*. 2021;1(11):1106

10. *Heart, Lung and Circulation's* Digital Collection of publications relating to COVID-19 is available at (www.heartlungcirc.org). The guidance was jointly developed by the Australian Technical Advisory Group on Immunisation (ATAGI) and the Cardiac Society of Australia and New Zealand (CSANZ).

11. Takuva S, Takalani A, Seocharan I, et al. Safety of the single-dose Ad26.CoV2.S vaccine among healthcare workers in the phase 3b Sisonke study in South Africa. medRxiv, 2021

12. COVID Data Tracker. Centers for disease control and prevention 2020. <https://covid.cdc.gov/covid-data-tracker>

13. VAERS – Data n.d <https://vaers.hhs.gov/data.html>

14. Myocarditis and Pericarditis After mRNA COVID-19 Vaccination [Internet]. Centers for Disease Control and Prevention. 2021 [cited 5 March 2022]. Available from: <https://www.cdc.gov/>

15. Kariyanna P.T., Sutarjono B., Grewal E., Singh K.P., Aurora L., Smith L., Chandrakumar H.P., Jayarangaiah A., Goldman S.A., Salifu M.O., McFarlane I.M. A systematic review of COVID-19 and myocarditis. *Am J Med Case Rep*. 2020;8(9):299–305.

16. Siripanthong B., Nazarian S., Muser D., Deo R., Santangeli P., Khanji M.Y., Cooper L.T., Jr., Chahal C.A.A. Recognizing COVID-19-related myocarditis: the possible pathophysiology and proposed guideline for diagnosis and management. *Heart Rhythm*. 2020;17(9):1463–1471.

17. Kociol R.D., Cooper L.T., Fang J.C., Moslehi J.J., Pang P.S., Sabe M.A., Shah R.V., Sims D.B., Thiene G., Vardeny O. Recognition and initial management of fulminant myocarditis: a scientific statement from the American heart association. *Circulation*. 2020;141(6):e69–e92.