Medical Sciences 2021 Vol. 9 (4), p. 175-180

e-ISSN: 2345-0592
Online issue
Indexed in *Index Copernicus*

Medical Sciences

Official website:
www.medicsciences.com

Laryngeal tuberculosis: a case report

Agnė Pašvenskaitė[1], Deimantė Bajoriūnaitė[2], Roberta Buginytė[2], Virgilijus Ulozas[1]

[1] *Lithuanian University of Health Sciences, Department of Otorhinolaryngology, Kaunas, Lithuania*

[2]*Lithuanian University of Health Sciences, Academy of Medicine, Kaunas, Lithuania*

Abstract

Background. Laryngeal tuberculosis is a rare form of tuberculosis that usually develops due to direct spread from a bronchus or hematogenous spread. The most common symptom related to laryngeal tuberculosis is hoarseness which also can be led by dysphagia, odynophagia, cough, or nonspecific symptoms like fever or localized pain. To confirm laryngeal tuberculosis, histopathologic examination is necessary because it can mimic laryngeal cancer. Diagnosis of laryngeal tuberculosis is made through a combination of a comprehensive otorhinolaryngological examination, imaging, laboratory and histological analysis.

Case report. We describe the case of a 62-year-old Lithuanian man who presented with the clinical picture of laryngeal cancer, but which turned out to be tuberculosis. We illustrate the difficulty of recognizing laryngeal tuberculosis both clinically and even with radiological examination.

Discussion. Laryngeal tuberculosis is a rare condition that can mimic laryngeal cancer. In male patients with a history of smoking and complaining of dysphonia, odynophagia, and cough LT is a diagnosis to be considered.

Keywords: Laryngeal tuberculosis, tuberculosis, dysphagia, odynophagia, cough.

1. Introduction

Tuberculosis (TB) is a chronic bacterial infection induced by a bacterial species belonging to the Mycobacterium tuberculosis complex. Laryngeal tuberculosis (LT) is a rare disease, with an incidence of less than 1% [1,2]. The disease usually results from pulmonary tuberculosis due to direct spread from contaminated sputum, although it might be localized in the larynx as a primary lesion without any pulmonary involvement [3-5]. Delays in diagnosing LT could be explained by seemingly irrelevant symptoms such as hoarseness as only severe symptoms of later stages (laryngeal stenosis with dyspnoea and stridor, dysphagia, otalgia, odynophagia, and haemoptysis) lead these patients to doctor's consultation [6]. Endoscopic laryngeal examination (video laryngostroboscopy, flexible endoscopy, contact endoscopy) performed by an otorhinolaryngologist is the first diagnostic tool in LT suspicion. Besides, laryngoscopic alterations in a case of LT can often mimic laryngeal cancer [7,8]. Direct laryngoscopy with a biopsy is mandatory to establish a definitive diagnosis. Diagnosis of LT is confirmed by identification of a caseating granuloma in a biopsy specimen [9,10]. This report presents a case of LT in a patient with primary pulmonary tuberculosis.

2. Case report

Patient's anamnesis. A 62-year-old male presented at the Outpatient Office of the Department of Otorhinolaryngology, Hospital of Lithuanian University of Health Sciences, Kaunas Klinikos in September 2020. The patient was complaining of difficulty in swallowing and a slight loss of weight for over 3 months. The patient was previously treated for fungal laryngeal infection and also tested for TB, but the diagnosis was rejected. Social and occupational history was significant for working in a dusty environment and smoking for many years.

Otorhinolaryngological examination. A comprehensive otorhinolaryngological examination including video laryngostroboscopy and neck palpation was carried out. During laryngeal inspection, necrotic masses were observed on the laryngeal surface of the epiglottis. Vocal folds were mobile and intact. Initial laboratory examinations revealed slightly elevated C-Reactive Protein, microcytic microchromic anemia.

Treatment strategy. In suspicion of possible epiglottic tumor, direct microlaryngoscopy was performed and multiple biopsy samples were taken on the 3rd of September, 2020 (Figure 1). No specific alterations in piriform sinuses, aryepiglottic folds, valleculas, ventricles or vocal folds were identified. Biopsy results (No. H1377-20 07/09/2020) revealed some necrotic granuloma-like structures with solitary Langhans giant cells and no tumourous changes with the suggestion of LT.

Additional examination:

- **Chest X-ray (07/09/2020):** multiple small merging focal infiltration in the middle lobe and basal parts of the right lung.

  Conclusion: more detailed examination is required (Chest-Thorax CT scan).
- **Contrast-enhanced chest CT (09/09/2020):** groups of small clustered micro focuses which partially form a tree-in-bud sign. In the background of right lung L1 and S6 observable solitary 0.8-1.1 cm size focus (Figure 2).
- **Neck-Larynx CT with i/v contrast (09/09/2020):** free part of epiglottis unevenly

thickened, inferior epiglottic contour uneven, observable epiphytical growing masses with a non-intensive accumulation of contrast (Figure 3). A suspicious lymph node in the VI group of neck lymph nodes was observed. Observable lungs' upperparts are with clusters of small focuses.

Conclusion: alterations in epiglottis are non-specific. Evaluating epiglottic and pulmonary alterations does not deny a diagnosis of tuberculosis, but it should be differentiated with hypervascular tumor.

- **Fibrobronchoscopy (09/09/2020):** bronchial mucosa is slightly hyperemic, edematous, with a small amount of unclear mucus on both sides. Bronchial sputum was collected for histopathological analysis.
- **Multidisciplinary team meeting (09/09/2020)** composed of otorhinolaryngologist, pulmonologist, pathologist conclusion: for further treatment of TB the patient should be treated in a tuberculosis hospital with a recommendation of otorhinolaryngological examination after the treatment of TB.

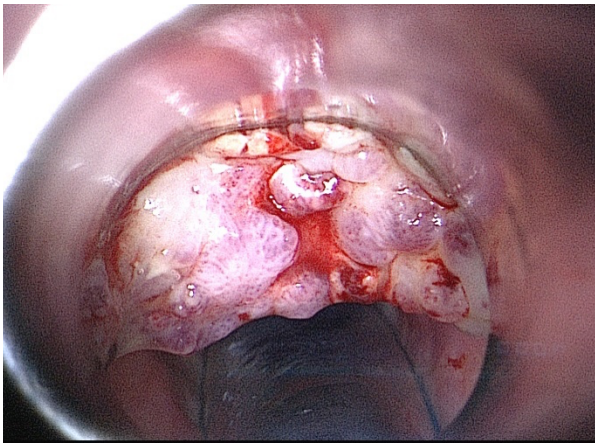

Figure 1. Direct microlaryngoscopy: necrotic masses on the laryngeal surface of epiglottis.

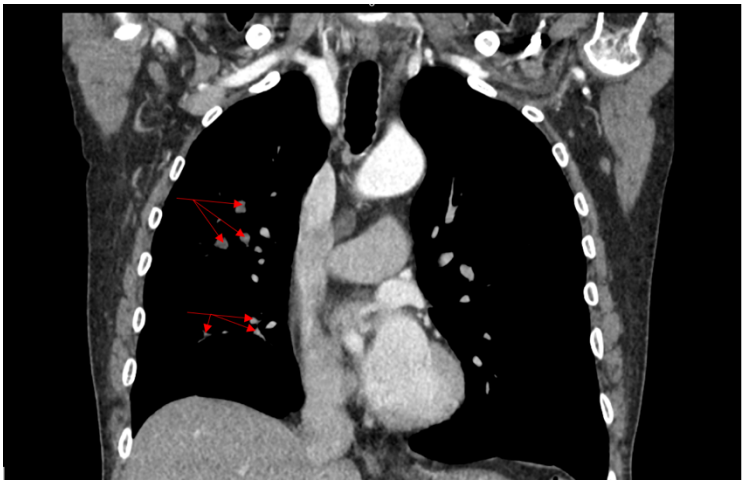

Figure 2. Contrast Chest CT with multiple pulmonary foci

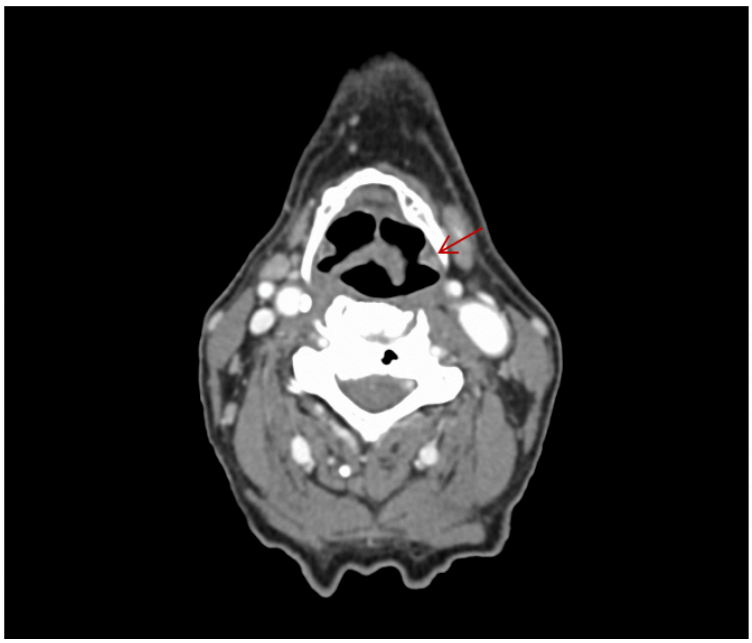

Figure 3. Contrast Neck-Larynx CT: red arrows indicate epiphytical growing masses of the epiglottis.

3. Discussion

LT is the most common granulomatous laryngeal disease [11]. In most cases, it can be simply misdiagnosed due to no pathognomonic or little worrying symptoms such as hoarseness [12]. The attention should be focused on men aged 40-60 with risk factors like HIV, diabetes, immunosuppressive drug use, and a history of smoking [13,14]. Also, endoscopic tests demonstrate more destructive alterations in smokers than in non-smokers, leading to the hypothesis that smoke results in a chronic effect on the laryngeal mucous membrane [15].

LT mostly affects epiglottis, vocal and vestibular folds. However, it can spread to any part of the larynx. [16]. Symptoms are associated with affected sites, manifesting in dysphonia, odynophagia and weight loss, dyspnea on exertion, and cough [17].

Diagnosis of LT is made through a combination of a comprehensive otorhinolaryngological examination, imaging, laboratory, and histological analysis [18]. The gold standard for confirming TB is mycobacterium tuberculosis culture, but the growth cycle is long and may delay the treatment. Another method that is quick and simple is acid-fast staining, but it has a low positive rate. Moreover, in LT cases smear and culture might be ineffective due to low concentrations of bacilli in the larynx [19]. The larynx is a secondary location for TB infection [16]. For this reason, the first recommended step in diagnosing TB is Chest X-ray or/and Chest CT to assess the pulmonary involvement [16]. Another challenge in diagnosing LT is its inconsistent lesion presentation in the laryngoscopic examination – LT can mimic other diseases such as laryngeal form of gastroesophageal reflux disease, leukoplakia, contact ulcer, polyp, or malignancy [20]. To understand better the spread of the disease CT scan and/or MR imaging is recommended. Signs of laryngeal TB in CT include focal thickening or mass in the epiglottis, vocal folds, and paralaryngeal tissues [7]. Histopathological analysis might show granulomas with giant cells with or without necrosis, tuberculosis mycobacterium, positive results of acid-fast stain [19].

A well-known drug-susceptible TB treatment includes a 6-month course of isoniazid (INH), rifampin (RIF), pyrazinamide (PZA), and ethambutol (EMB), when all four drugs are used for 2 months, with the continuation of INH and RIF for 4 more months. In cases where initiation of treatment is delayed the course could be extended up to 9 months. In cases of rifampicin-resistant or multidrug-resistant tuberculosis, it is recommended to use second-line drug combinations, and the treatment regimen is increased to at least 18-months [18].

To conclude, LT is a rare condition that can often mimic laryngeal cancer. In male patients with a history of smoking and complaining of dysphonia, odynophagia, and cough LT is a diagnosis to be considered.

References

1.Matsuura H, Yamaji Y. Laryngeal tuberculosis: a forgotten disease. QJM. 2017;110(8):521. doi:10.1093/qjmed/hcx078

2. Harney M, Hone S, Timon C, et al. Laryngeal tuberculosis: important diagnosis. J Laryngol Otol 2000; 114: 878–80

3.E Özüdogru, H Çakli, EE Altuntas,1 and MK Gürbüz. Effects of laryngeal tuberculosis on vocal fold functions: case report. Acta Otorhinolaryngol Ital. 2005 Dec; 25(6): 374–377.

4. Lim JY, Kim KM, Choi EC, Kim YH, Kim HS, et al. (2006) Current clinical propensity of laryngeal tuberculosis: review of 60 cases. Eur Arch Otorhinolaryngol 263: 838-842.

5. Nalini B, Vinayak S: Tuberculosis in ear, nose, and throat practice: its presentation and diagnosis. Am J Otolaryngol. 2006, 27: 39-45. 10.1016/j.amjoto.2005.07.005.

6. Lazarus AA, Thilagar B: Tuberculosis of pericardium, larynx, and other uncommon sites, Dis Mon 53:46–54, 2007

7. Cengiz A, Göksel S, Başal Y, Taş Gülen Ş, Döğer F, Yürekli Y. Laryngeal Tuberculosis Mimicking Laryngeal Carcinoma on 18F-FDG PET/CT Imaging. 18F-FDG PET/BT Görüntülemede Maligniteyi Taklit Eden Laringeal Tüberküloz. *Mol Imaging Radionucl Ther*. 2018;27(2):81-83. doi:10.4274/mirt.44366

8. Lim JY, Kim KM, Choi EC, Kim YH, Kim HS, Choi HS: Current clinical propensity of laryngeal tuberculosis: review of 60 cases. Eur Arch Otorhinolaryngol. 2006, 263: 838-842. 10.1007/s00405-006-0063-5.

9. Kiakojuri K, Hasanjani Roushan MR. Laryngeal tuberculosis without pulmonary involvement. Caspian J Intern Med. 2012;3(1):397-399.

10. Jeana L. Benwill, Juan C. Sarria, Laryngeal tuberculosis in the United States of America: A forgotten disease. Scandinavian Journal of Infectious Diseases, 2014; 46: 241–249

11.Cole AE, Heaton D, Chekairi A. Laryngeal tuberculosis: a rare cause of critical airway obstruction. BMJ Case Rep. 2018;2018:bcr2017222841. Published 2018 Jan 17. doi:10.1136/bcr-2017-222841

12.Paulauskienė I, Mickevičienė V. Dysphonia - the single symptom of rifampicin resistant laryngeal tuberculosis. Open Med (Wars). 2016;11(1):63-67. Published 2016 Mar 26. doi:10.1515/med-2016-0013

13. Jindal SK, Jindal A, Agarwal R. Upper Respiratory Tract Tuberculosis. Microbiol Spectr. 2016;4(6):10.1128/microbiolspec.TNMI7-0009-2016. doi:10.1128/microbiolspec.TNMI7-0009-2016

14. Corbett EL, Watt CJ, Walker N, Maher D, Williams BG, Raviglione MC et al. The growing burden of tuberculosis: global trends and interactions with the HIV epidemic. Arch Intern Med. 2003 May 12; 163(9):1009-21.

15.Kurokawa M, Nibu K, Ichimura K, Nishino H. Laryngeal tuberculosis: A report of 17 cases. Auris Nasus Larynx. 2015;42(4):305-310. doi:10.1016/j.anl.2015.02.012

16. Eltilib M, Boyd W, Saramago I, Askin F, Zamora C. Laryngeal tuberculosis mimicking malignancy: A case report. Clin Case Rep. 2020;8(7):1209-1212. Published 2020 Apr 21. doi:10.1002/ccr3.2882

17. Reis JGC, Reis CSM, Costa DCSd, Lucena MM, Schubach AdO, et al. Factors Associated with Clinical and Topographical Features of Laryngeal Tuberculosis. 2016; PLOS ONE 11(4): e0153450. https://doi.org/10.1371/journal.pone.0153450

18. Qian X, Albers AE, Nguyen DTM, et al. Head and neck tuberculosis: Literature review and meta-analysis. Tuberculosis (Edinb). 2019;116S:S78-S88. doi:10.1016/j.tube.2019.04.014

19.Yu Z, Lu R, Gan M, Tu X, He Z. Mycobacterial identification on homogenised biopsy facilitates the early diagnosis and treatment of laryngeal tuberculosis. Open Med (Wars). 2020;15(1):508-512. Published 2020 Jun 5. doi:10.1515/med-2020-0171

20. Agarwal R, Gupta L, Singh M, et al. Primary Laryngeal Tuberculosis: A Series of 15 Cases. Head Neck Pathol. 2019;13(3):339-343. doi:10.1007/s12105-018-0970-y